

High-Speed Ultra-High-Resolution Optical Coherence Tomography Findings in Hydroxychloroquine Retinopathy

Julio A. Rodriguez-Padilla, MD; Thomas R. Hedges III, MD; Bryan Monson, BS; Vivek Srinivasan, MS; Maciej Wojtkowski, PhD; Elias Reichel, MD; Jay S. Duker, MD; Joel S. Schuman, MD; James G. Fujimoto, PhD

Objectives: To compare structural changes in the retina seen on high-speed ultra-high-resolution optical coherence tomography (hsUHR-OCT) with multifocal electroretinography (mfERG) and automated visual fields in patients receiving hydroxychloroquine.

Methods: Fifteen patients receiving hydroxychloroquine were evaluated clinically with hsUHR-OCT, mfERG, and automated visual fields. Six age-matched subjects were imaged with hsUHR-OCT and served as controls.

Results: Distinctive discontinuity of the perifoveal photoreceptor inner segment/outer segment junction and thinning of the outer nuclear layer were seen with hsUHR-OCT

in patients with mild retinal toxic effects. Progression to complete loss of the inner segment/outer segment junction and hyperscattering at the outer segment level were seen in more advanced cases. The mfERG abnormalities correlated with the hsUHR-OCT findings. Asymptomatic patients had normal hsUHR-OCT and mfERG results.

Conclusion: Distinctive abnormalities in the perifoveal photoreceptor inner segment/outer segment junction were seen on hsUHR-OCT in patients receiving hydroxychloroquine who also were symptomatic and had abnormalities on automated visual fields and mfERG.

Arch Ophthalmol. 2007;125:775-780

THE ANTIMALARIAL DRUG HYDROXYCHLOROQUINE, used in the treatment of rheumatologic disease, has been associated with the development of retinopathy. The long-term incidence of hydroxychloroquine retinopathy has been estimated at 0.5% when recommended dosages (≤ 6.5 mg/kg per day) are used.¹ Even though this incidence may be considered low, the retinopathy can have devastating effects on vision. In our experience, as patients are receiving the drug for prolonged periods, retinal toxic effects from hydroxychloroquine are becoming more common.

The American Academy of Ophthalmology has published guidelines for screening based on risk factors for toxic effects, including dosage, duration of use, body habitus, renal or liver function, concomitant retinal disease, and age.² However, there is no definitive clinical test for the identification of hydroxychloroquine toxic effects before the appearance of fundoscopic changes and symptomatic loss of vision.³

Optical coherence tomography (OCT) is a technique that provides cross-sectional imaging of tissue morphology in vivo.⁴ The Stratus OCT system (Carl Zeiss Meditec, Dublin, Calif) is widely used in ophthalmology practice and can provide cross-sectional images and quantitative information on retinal pathological abnormalities.^{5,6} An image with 10- μ m axial resolution and 512 axial scans may be acquired in 1.3 seconds using Stratus OCT.

A research prototype of a high-speed, ultra-high-resolution OCT (hsUHR-OCT) ophthalmic imaging system was recently developed by our group for use in the ophthalmology clinic at the New England Eye Center, Boston, Mass. This system uses spectral or Fourier domain detection, allowing for a dramatic improvement in the cross-sectional image resolution and acquisition speed. The system allows for axial resolution of approximately 3.5 μ m compared with the 10- μ m resolution in standard OCT, and it also allows for imaging speeds that are approximately 75 times faster than standard OCT.⁶⁻⁸ Ultra-high-resolution OCT enables superior visualization of retinal morphology in a num-

Author Affiliations: New England Eye Center, Tufts–New England Medical Center, Tufts University, Boston, Mass (Drs Rodriguez-Padilla, Hedges, Reichel, and Duker and Mr Monson); Department of Electrical Engineering and Computer Science and Research Laboratory of Electronics, Massachusetts Institute of Technology, Cambridge (Mr Srinivasan and Drs Wojtkowski and Fujimoto); Institute of Physics, Nicolaus Copernicus University, Torun, Poland (Dr Wojtkowski); and Department of Ophthalmology, University of Pittsburgh, Pittsburgh, Pa (Dr Schuman).

Table. Clinical, High-Speed Ultra-High-Resolution Optical Coherence Tomography, and Multifocal Electroretinogram Findings From Patients Receiving Hydroxychloroquine

Patient No./ Age, y	Hydroxychloroquine Dosage, mg/d	Diagnosis	Treatment, y	Symptoms	Visual Acuity, OD, OS	Color Vision	Visual Fields	mfERG Results	UHR-OCT Results	Fundi
1/46	400	SLE	10	Blind area	20/20, 20/20	Normal	Small pericentral scotomas	Perifoveal depression	Perifoveal IS/OS loss	Punctate retinal pigment changes
2/66	400	SLE	3	Blind area	20/25, 20/25	Reduced	Pericentral scotomas	Perifoveal depression	Perifoveal IS/OS loss	Normal
3/62	400	SLE	12	None	20/30, 20/30	Normal	Normal	Normal	Normal	Mild granular changes
4/60	400	RA	13	Flashing lights	20/25, 20/20	Normal	Not examined	Perifoveal depression	Perifoveal IS/OS loss	Bull's-eye changes
5/84	400	RA	7	Blind area	20/30, 20/50	Reduced	Enlarged blind spots	General depression	Generalized IS/OS loss and disruption	Peripapillary atrophy
6/63	NA	RA	10	Colors dim	20/20, 20/20	Reduced	Normal	Perifoveal depression	Drusen	Normal
7/31	400	RA	5	None	20/15, 20/20	Normal	Not examined	Normal	Normal	Normal
8/88	400	RA	6	Blurry vision	20/40, 20/40	Reduced	Large pericentral scotomas	General depression	Generalized IS/OS loss and disruption	Normal
9/34	200	SLE	6.5	None	20/20, 20/20	Normal	Not examined	Not done	Normal	Normal
10/64	200	SLE	15	Visual loss	CF 2 ft, 20/25	Reduced	Central pericentral scotomas	General depression	Generalized IS/OS junction loss and disruption	Mild pigment changes
11/29	400	RA	7	None	20/20, 20/20	Normal	Normal	Normal	Normal	Normal
12/64	400	RA	28	Visual loss	20/25, 20/20	Reduced	Pericentral scotomas	General depression	Generalized IS/OS junction loss and disruption	Bull's-eye changes
13/56	400	SLE	18	None	20/20, 20/20	Normal	Normal	Normal	Normal	Normal
14/60	400	SLE	20	None	20/30, 20/40	Normal	Normal	Perifoveal depression	Thinning of IS/OS junction	Normal
15/34	400	SLE	9	Visual loss	20/25, 20/25	Normal	Ring scotoma	Perifoveal depression	Generalized IS/OS junction loss and disruption	Bull's-eye changes

Abbreviations: CF, counting fingers; IS/OS, inner segment/outer segment; mfERG, multifocal electroretinogram; NA, not applicable; RA, rheumatoid arthritis; SLE, systemic lupus erythematosus; UHR-OCT, ultra-high-resolution optical coherence tomography.

ber of retinal pathological abnormalities.^{9,10} High-speed UHR-OCT further improves visualization by acquiring high-transverse-pixel-density, high-definition images.

We have not observed distinctive abnormalities on standard (Stratus) OCT images from patients receiving hydroxychloroquine who have had mild loss of vision and abnormal multifocal electroretinogram (mfERG) findings. Therefore, we obtained hsUHR-OCT images from 15 patients receiving hydroxychloroquine to determine whether hsUHR-OCT could show distinctive structural changes that might occur before patients lose vision or develop abnormalities on mfERG.

METHODS

Fifteen patients referred to the New England Eye Center for evaluation of hydroxychloroquine maculopathy were studied. Participants underwent complete ophthalmic examination, hsUHR-OCT imaging, automated perimetry (Humphrey program 10-2 with white test lights; Humphrey Field Analyzer II; Carl Zeiss Meditec, Inc), and mfERG (VERIS system; Electro Diagnostic Imaging, Inc, San Mateo, Calif). Five patients also underwent testing with Stratus OCT (Carl Zeiss Meditec, Inc) on the same day as the other tests. Six age-matched patients with normal visual function were studied with hsUHR-OCT, and their images were randomly selected from the files collected in the hsUHR-OCT laboratory to be used as normal controls. We chose 6 controls because that was the same number of patients with normal hsUHR-OCT images.

Following pupillary dilation with 1% tropicamide, hsUHR-OCT imaging was performed using a linear scan protocol with 8192 A-scans per image as previously described.⁷

All of the hsUHR-OCT images (patients and controls) were evaluated by 2 observers (E.R. and J.S.D.) who are retinal specialists experienced in the evaluation of OCT and hsUHR-OCT images. The images were masked as to patient identity and history of use of hydroxychloroquine. The observers were asked to classify the images as showing definite hydroxychloroquine toxic effects, nonspecific abnormalities, or normal structure.

The study was approved by the institutional review board of Tufts–New England Medical Center. All of the participants gave informed consent for participation in the study.

RESULTS

Patient ages ranged from 29 to 88 years. One patient (patient 6) was male. Seven patients had systemic lupus erythematosus; 1 patient (patient 14) was treated for suspected systemic lupus erythematosus; the rest (7 patients) were receiving treatment for rheumatoid arthritis (**Table**). Overall, the sample of subjects included controls (2 men and 4 women; age range, 20-70 years) and patients receiving hydroxychloroquine, of whom some were without clinical evidence of maculopathy (normal visual acuity, normal visual field, and nonspecific fundus findings) and others had clinical and electrophysiological evidence of hydroxychloroquine maculopathy.

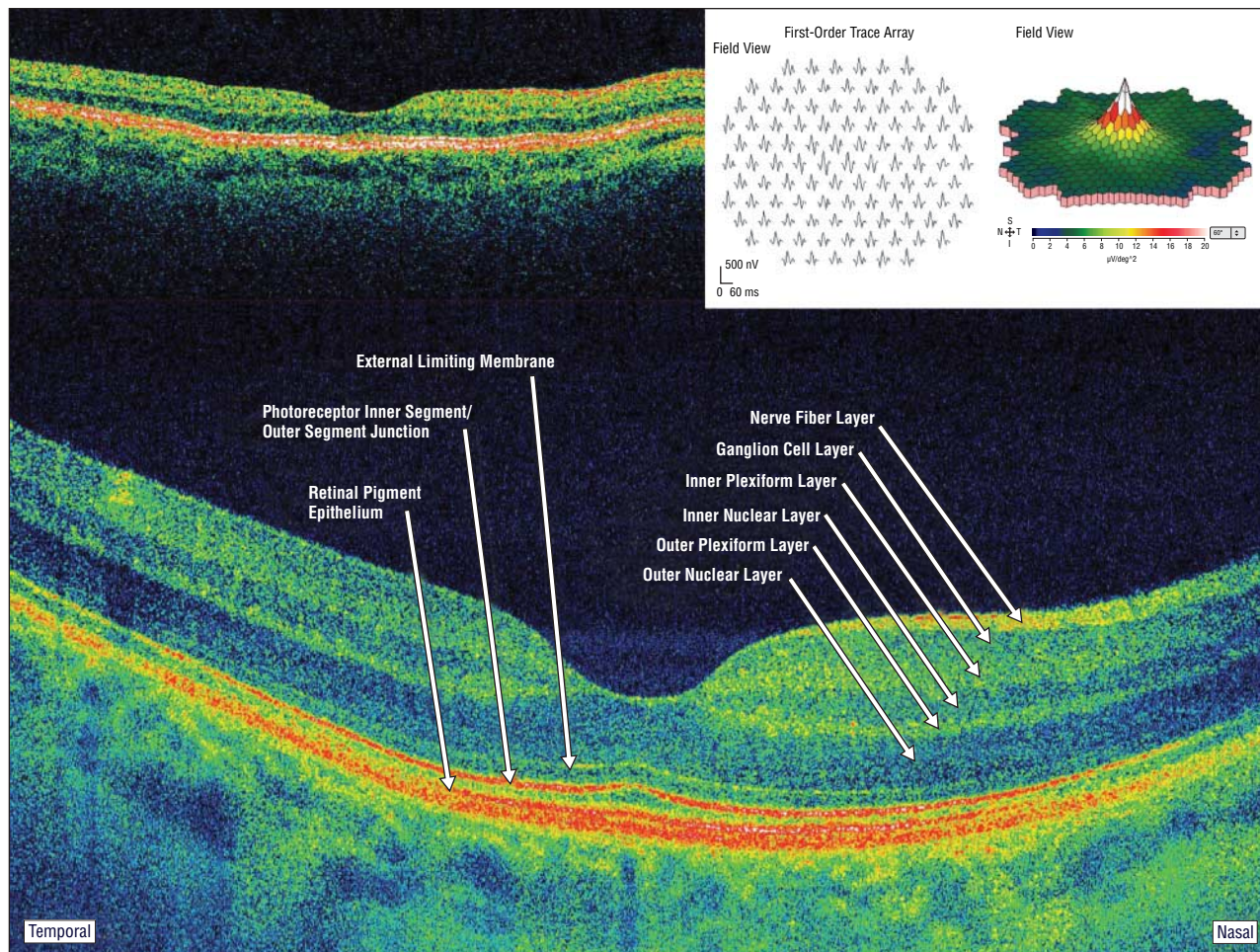


Figure 1. Case 11. Normal Stratus optical coherence tomographic image (upper left) and normal multifocal electroretinogram (upper right). High-speed ultra-high-resolution optical coherence tomography allows for detailed visualization of the retinal structure on the level of individual retinal layers.

Multifocal ERG signals were evaluated using the averaged concentric ring analysis provided by the VERIS software. Patients without clinical (visual field or fundoscopic) evidence of hydroxychloroquine maculopathy had mfERG results that were normal when compared with reference values, with a progressive decrease in amplitude as the distance from the fovea increased (patients 3, 7, 11, and 13) (**Figure 1**). Decreased amplitudes were noted in patients with clinical evidence of mild to moderate hydroxychloroquine retinopathy (visual field defects or pigmentary retinopathy), particularly in zones 2 and 3, which represent 5° and 10° away from the fovea, respectively. Zones 5 and 6 were relatively spared (patients 1, 2, 4, 5, 6, 8, and 12). Patients with advanced retinopathy had relatively flat signals, even in the foveal center (patients 10 and 15). Patient 14 had mildly decreased amplitudes in the central 3 rings when compared with reference values but overall had a normal pattern of amplitudes with increasing foveal eccentricity.

Normal hsUHR-OCT results were seen in 6 cases (patients 3, 7, 9, 11, 13, and 14). Abnormalities on hsUHR-OCT appeared to progress in severity from distinctive loss of the perifoveal inner segment/outer segment (IS/OS) photoreceptor junction with preservation of the fovea to more generalized loss of the IS/OS junction. Milder hydroxychloroquine toxic effects were observed in pa-

tients 1, 2, and 6 (**Figure 2** and **Figure 3**). The length of treatment in these mildly affected cases was 10 to 13 years. Their mfERGs showed perifoveal depression with a preserved central peak. Furthermore, the IS/OS junction was preserved in the foveal area in these cases in which visual acuity was also normal and the paracentral scotomas were relatively small.

More extensive abnormalities were disruption of the IS/OS junction including the foveal region as well as more severe thinning of the outer nuclear layer. In these patients (patients 5 and 8), there were hyperscattering bands and penetration of OCT beams deep to layers corresponding to the retinal pigment epithelium, choroid, photoreceptors, and the external limiting membrane, which may have been due to disrupted remnants of the photoreceptors (**Figure 3**). The length of treatment in these cases ranged from 3 to 28 years. Some patients (patients 4, 12, and 15) showed hyperscattering but still had some preservation of the foveal IS/OS junction. They retained visual acuities of 20/25 or better. These 3 patients all had bull's-eye lesions. One patient (patient 10) had severe abnormalities in one eye and less severe abnormalities in the other. All of the advanced cases had abnormal mfERG results that showed foveal as well as generalized depression of cone responses, and their visual fields showed dense paracentral scotomas.

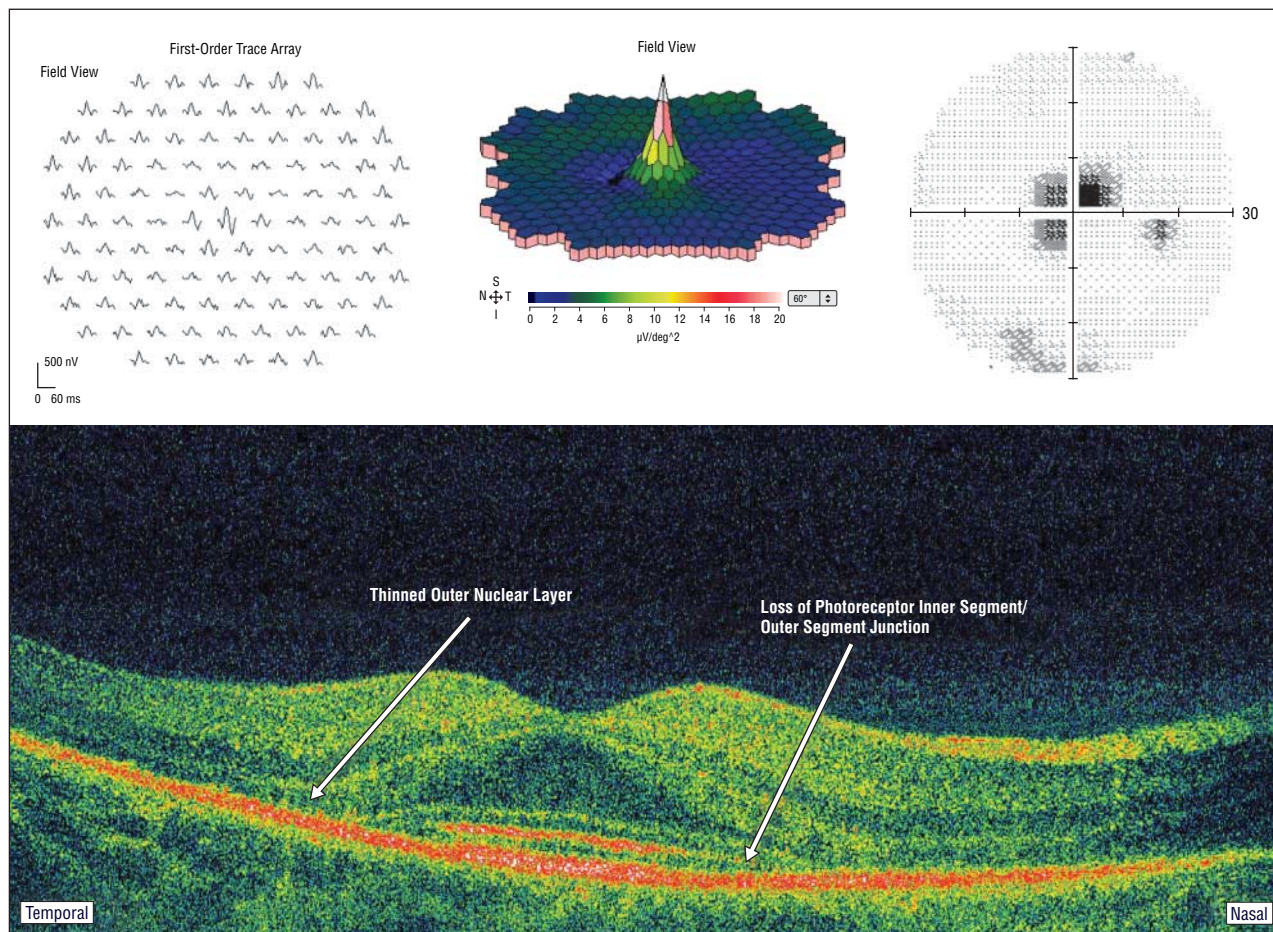


Figure 2. Case 1. Multifocal electroretinogram (upper left) shows perifoveal depression with preserved central peak. Visual field shows central scotoma. High-speed ultra-high-resolution optical coherence tomography shows thinning of the outer nuclear layer and loss of the photoreceptor inner segment/outer segment junction layer.

When 2 retinal specialists (E.R. and J.S.D.) evaluated in a masked fashion the hsUHR-OCT images of both patients and controls, they determined that 4 patients receiving hydroxychloroquine had no evidence of maculopathy. In these cases, hsUHR-OCT showed a clearly defined line of high reflectivity in the posterior retina representing the photoreceptor IS/OS junction, which was indistinguishable from that in controls. These patients had been receiving hydroxychloroquine dosages of 400 mg/d for 4 to 18 years.

Of 2 patients (patients 13 and 14) without definite scotomas and minimal changes on mfERG, one was judged as having abnormal hsUHR-OCT images by 1 of the masked examiners and the other was judged as having abnormal hsUHR-OCT images by the second examiner. However, the examiners did not think the images were distinguishable from those of other macular disorders. In particular, if IS/OS junction loss was not clearly perifoveal with foveal sparing, the distinction could not be made with certainty. The lengths of treatment in these cases were 18 and 20 years, respectively.

Of the remaining 9 patients with clinical evidence of hydroxychloroquine maculopathy, both examiners identified all of the cases as either definite hydroxychloroquine retinopathy or not specifically abnormal. The examiners were in absolute agreement in 4 (44%) of these

9 patients (no discrepancy even between definite toxic effects vs abnormal results). They disagreed in patients 2, 5, 8, and 10. All of these cases showed foveal as well as perifoveal abnormalities. One examiner graded 1 of our control subjects as having abnormal results but not showing hydroxychloroquine toxic effects. When both patients and controls were considered, the evaluators were in absolute agreement in 14 (67%) of the cases.

COMMENT

Hydroxychloroquine toxicity appears to first affect the retinal ganglion cells and the photoreceptors, especially in the perifoveal region.¹¹ The drug also has affinity for pigmented cells, including the retinal pigment epithelium, perhaps as a secondary effect on the photoreceptor OSs. This pathophysiological mechanism seems to be corroborated by our findings in which hsUHR-OCT showed abnormalities of the outer retinal layers. We have not yet been able to see distinctive effects on the ganglion cells on hsUHR-OCT. In the absence of histopathological specimens, hsUHR-OCT is the closest equivalent to visualization of structural damage caused by the drug. However, it must be kept in mind that OCT images show variations in optical scattering properties

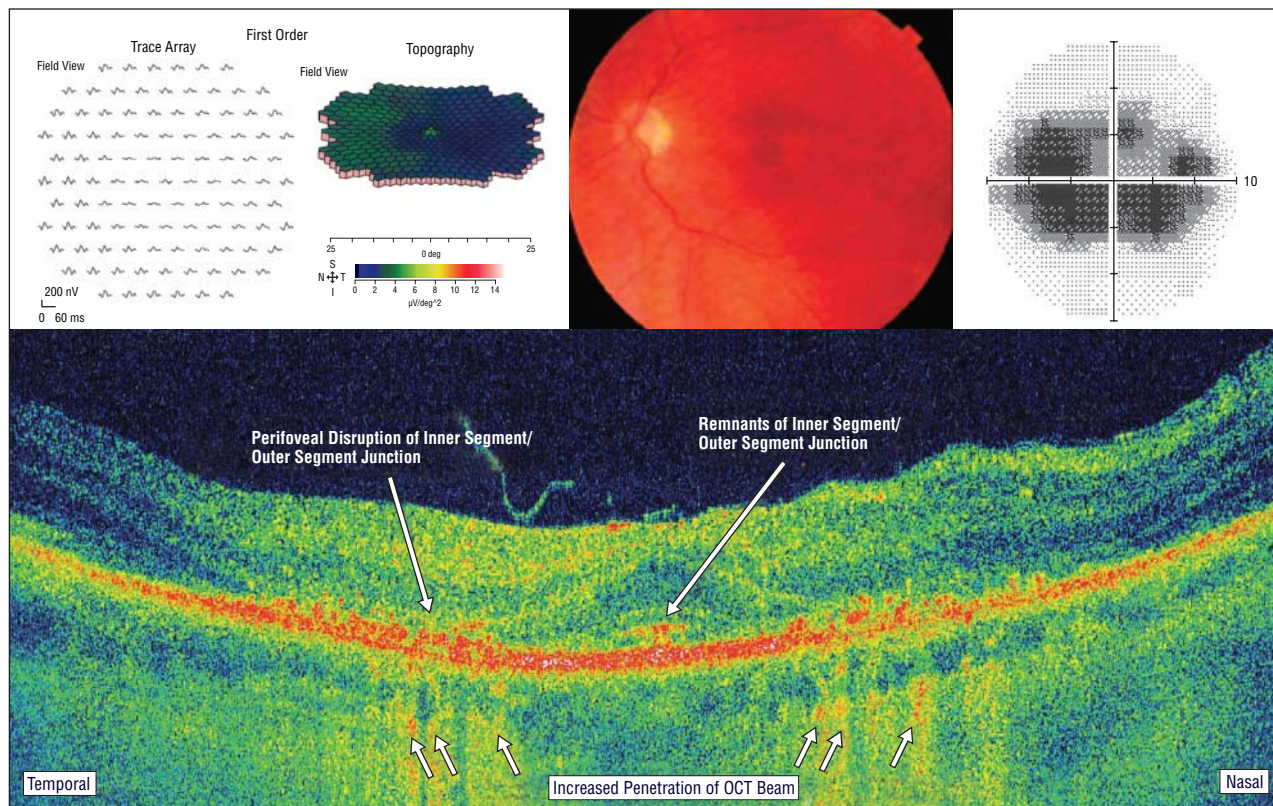


Figure 3. Case 12. Bull's-eye maculopathy, multifocal electroretinogram with foveal depression, and central scotoma in central 10°. High-speed ultra-high-resolution optical coherence tomography (OCT) shows severe loss of the photoreceptor inner segment/outer segment junction layer, thinned outer nuclear layer, and perifoveal hyperscattering as well as increased penetration of the optical coherence tomography beams into the choroid.

of different retinal tissues rather than variations in histopathological staining.

Our main intention was to determine whether early toxic effects from hydroxychloroquine could be detected by hsUHR-OCT before clinical signs or symptoms occurred in affected patients. We were also interested in how the structural findings from hsUHR-OCT correlated with those from other tests such as mfERG. One patient (patient 13) with normal electrophysiologic examination results had an hsUHR-OCT image that was judged abnormal, but not specifically owing to hydroxychloroquine, by one masked examiner. Another patient (patient 14) had abnormal mfERG results but no scotoma on visual field examination. The hsUHR-OCT image was judged abnormal, but not specifically owing to hydroxychloroquine, by another masked examiner. At this point, it is unclear whether these patients had early asymptomatic changes that could be predictive of maculopathy or whether the observed hsUHR-OCT abnormalities could be judged as definite evidence of hydroxychloroquine maculopathy on a case-by-case basis. Longer follow-up of these borderline cases is needed to determine whether hsUHR-OCT can definitely predict damage to the retina before symptoms occur.

Mild abnormalities on hsUHR-OCT (patients 1, 2, and 6) included loss of the innermost high reflectivity layer in the outer retina, which corresponds to the photoreceptor IS/OS junction. In addition, thinning of the outer nuclear layer in the perifoveal area was also noted. The mfERGs from these patients were consistent with hy-

droxychloroquine toxic effects, showing perifoveal depression with preservation of the central peak.¹²⁻¹⁴ These patients also had visual acuities of 20/25 or better and minimal visual field changes.

More advanced cases (patients 5, 8, 10, 12, and 15) showed more severe disruption of the photoreceptor IS/OS junction layer along with irregular scattering bands corresponding to remnants of photoreceptor OSs. Their mfERGs showed central depression or generalized depression as well as larger pericentral scotomas on visual field testing. In patients with bull's-eye maculopathy (patients 4, 12, and 15), hsUHR-OCT showed disruption of photoreceptor OSs in addition to IS/OS loss in the perifoveal region but not in the fovea. Except in patient 15, these individuals had preserved visual acuity ($\geq 20/25$) and some preservation of foveal signals on mfERG.

The patient with the most severe maculopathy (patient 10) had a history of treatment with hydroxychloroquine for 15 years and lupus nephritis requiring kidney transplantation. In this case, the IS/OS junction was absent and there was marked hyperscattering and penetration of the hsUHR-OCT beams. Visual acuity was reduced and the mfERG was flat. Patient 2 developed maculopathy after the relatively short time of 3 years at a dosage of 400 mg/d. She had been treated for breast cancer. We are unsure whether the additional medical problems may have contributed to the early onset of her maculopathy.

Stratus OCT images were not obtained on the same visit as hsUHR-OCT images and mfERGs in all of the patients. In those who were evaluated with Stratus OCT (pa-

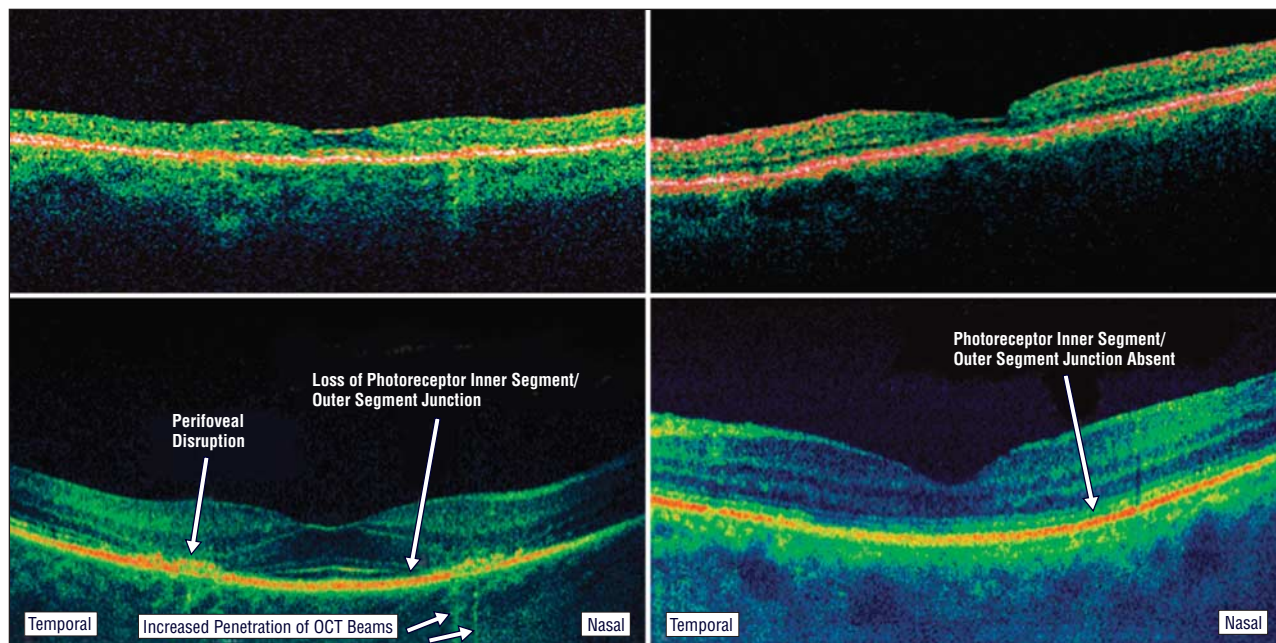


Figure 4. Comparison of Stratus optical coherence tomography (OCT) (upper panels) and high-speed ultra-high-resolution OCT (lower panels) in patient 4 (left) and patient 10 (right).

tients 3, 4, 6, 10, and 11), there was photoreceptor layer disruption visible only in some cases (patients 4, 6, and 10) (**Figure 4**). Patients 3 and 11 had normal hsUHR-OCT images, were asymptomatic, and had normal Stratus OCT images.

The level of abnormalities visualized with hsUHR-OCT seems to correlate with the severity of the maculopathy as measured with mfERG and visual field testing. Furthermore, in most cases, the changes observed with hsUHR-OCT stopped short of the foveal center, which could explain the preserved central peak in the mfERGs and preserved central acuity in typical cases.^{12,13}

Although patients 13 and 14 may have had minimal changes owing to hydroxychloroquine, thus far we have been unable to find an asymptomatic patient with evidence of definite damage on hsUHR-OCT. When the characteristic perifoveal IS/OS junction abnormalities can be demonstrated, hsUHR-OCT, like mfERG, can provide objective evidence of hydroxychloroquine toxic effects and may help confirm the presence of maculopathy in symptomatic patients.

Submitted for Publication: June 29, 2006; final revision received October 13, 2006; accepted November 20, 2006.

Correspondence: Thomas R. Hedges III, MD, Tufts–New England Medical Center, 750 Washington St, Boston, MA 02111 (thedges@tufts-nemc.org).

Financial Disclosure: Dr Wojtkowski is a scientific consultant for Optopol SA. Drs Schuman and Fujimoto receive royalties from intellectual property licensed by the Massachusetts Institute of Technology to Carl Zeiss Meditec.

Funding/Support: This study was supported in part by grants R01-EY11289, R01-EY13178, and P30-EY13078 from the National Institutes of Health, ECS-0119452 from the National Science Foundation, FA9550-040-1-0011

from the Air Force Office of Scientific Research, and F49620-01-1-0186 from the Medical Free Electron Laser Program.

REFERENCES

- Mavrikakis I, Sfikakis P, Mavrikakis E, et al. The incidence of irreversible retinal toxicity in patients treated with hydroxychloroquine: a reappraisal. *Ophthalmology*. 2003;110:1321-1325.
- Marmor MF, Carr RE, Easterbrook M, et al. Recommendations on screening for chloroquine and hydroxychloroquine retinopathy. *Ophthalmology*. 2002;109:1377-1382.
- Lee AG. Hydroxychloroquine screening. *Br J Ophthalmol*. 2005;89:521-522.
- Huang D, Swanson EA, Lin CP, et al. Optical coherence tomography. *Science*. 1991;254:1178-1181.
- Schuman JS, Puliafito CA, Fujimoto JG. *Optical Coherence Tomography of Ocular Diseases*. 2nd ed. Thorofare, NJ: Slack Inc; 2004.
- Wojtkowski M, Bajraszewski T, Gorczynska I, et al. Ophthalmic imaging by spectral optical coherence tomography. *Am J Ophthalmol*. 2004;138:412-419.
- Wojtkowski M, Srinivasan V, Fujimoto JG, et al. Three-dimensional retinal imaging with high-speed ultrahigh-resolution optical coherence tomography. *Ophthalmology*. 2005;112:1734-1746.
- Schmidt-Erfurth U, Leitgeb RA, Michels S, et al. Three-dimensional ultrahigh-resolution optical coherence tomography of macular diseases. *Invest Ophthalmol Vis Sci*. 2005;46:3393-3402.
- Drexler W, Morgner U, Ghanta RK, et al. Ultrahigh-resolution ophthalmic optical coherence tomography. *Nat Med*. 2001;7:502-507.
- Drexler W, Sattmann H, Hermann B, et al. Enhanced visualization of macular pathology with the use of ultrahigh-resolution optical coherence tomography. *Arch Ophthalmol*. 2003;121:695-706.
- Rosenthal AR, Kolb H, Bergsma D, et al. Chloroquine retinopathy in the rhesus monkey. *Invest Ophthalmol Vis Sci*. 1978;17:1158-1175.
- Maturi RK, Yu M, Weleber RG. Multifocal electroretinographic evaluation of long-term hydroxychloroquine users. *Arch Ophthalmol*. 2004;122:973-981.
- So SC, Hedges TR, Schuman JS, Amaro-Quireza ML. Evaluation of hydroxychloroquine retinopathy with multifocal electroretinography. *Ophthalmic Surg Lasers Imaging*. 2003;34:251-258.
- Penrose PJ, Tzekov RT, Sutter EE, et al. Multifocal electroretinography evaluation for early detection of retinal dysfunction in patients taking hydroxychloroquine. *Retina*. 2003;23:503-512.